

The Evaluation of the Relationship between Changes in Masseter Muscle Thickness and Tooth Clenching Habits of Bruxism Patients Treated with Botulinum Toxin A

Deniz Erdil¹, Nilsun Bagis¹, Hakan Eren², Melike Camgoz^{3*}, Kaan Orhan⁴

¹Department of Periodontology, Faculty of Dentistry, Ankara University, Ankara, Turkey, ²Department of Dentomaxillofacial Radiology, Faculty of Dentistry, Canakkale Onsekiz Mart University, Canakkale, Turkey, ³Faculty of Dentistry, Gazi University, Ankara, Turkey, ⁴Department of Dentomaxillofacial Radiology, Faculty of Dentistry, Ankara University, Ankara, Turkey

Abstract

Background: Bruxism is defined as recurrent masticatory muscle activity. Although there is not an agreed treatment method for bruxism, the application of botulinum toxin A (BT-A) has become a reliable lately. This study aimed to evaluate the correlation between the changes in masseter muscle thickness and clenching habits in bruxism patients treated with BT-A. **Methods:** Twenty-five patients, 23 females and 2 males, diagnosed with possible sleep bruxism were included in the study. The Fonseca Anamnestic Index was applied to the patients to determine their clenching habits and depression levels both before the treatment, and 6 months after it. The masseter muscle thickness was measured using ultrasonography before the treatment and 3 months and 6 months after the treatment. All the patients were injected with a total of 50 U of BT-A, 25 U to each masseter. **Results:** A statistically significant decrease in masseter muscle thickness was observed in the ultrasonography 3 and 6 months after the BT-A treatment. There was a statistically significant decrease in the Fonseca scores, in which the teeth clenching habits of the patients were evaluated 6 months after the treatment. Although there was a decrease in the depression levels of the patients 6 months after the treatment, this difference was not statistically significant. **Conclusion:** When the results of this study were evaluated, it was seen that the BT-A injections are an effective, safe, and side effect-free method in the treatment of bruxism and masseter hypertrophy.

Keywords: Botulinum toxin A, bruxism, depression, masseter hypertrophy, ultrasonography

INTRODUCTION

Bruxism is defined as recurrent masticatory muscle activity characterized by clenching, grinding, and/or pushing the mandible forward.^[1] The etiology of bruxism includes psychosocial (i.e. stress and anxiety, and depression), pathophysiological, genetic, and exogenous (i.e. alcohol consumption, medication, smoking) factors.^[2] This is a risk factor that may result in the damaging of the stomatognathic structures.^[3] When bruxism is present, this causes tooth fracture, abrasion, mobility, complications of dentures, temporomandibular disorders (TMD), pain in masticatory muscles, fatigue, and hypertrophy of masseter muscle.^[4-7] Two different forms of bruxism are awake bruxism and sleep bruxism, which have different etiologies. Awake bruxism may be the result of anxiety or psychosocial disorders.^[8] There

are a series of studies discussing the relationship between bruxism and personality, psychosocial factors, and anxiety in the literature.^[9] Gungormus and Erciyas stated that anxiety and depression are higher in people with bruxism in their study evaluating the relationship between bruxism that occurs and symptoms of anxiety and depression.^[10]

Biting force is produced mainly by masseter, temporal, and medial pterygoid muscles which are masticatory muscles responsible for closing the mandible. All three muscles work together in the closing action of the mandible, and therefore contribute to the general biting force. The masseter muscle

Address for correspondence: Dr. Melike Camgoz, Gazi University Faculty of Dentistry, Ogretim Uyeleri (VIP) Klinigi Biskek Cd 1. Sk No.4, Emek/Cankaya, Ankara, Turkey. E-mail: mlkozcan@yahoo.com

Received: 20-05-2022 Revised: 07-06-2022 Accepted: 29-06-2022 Available Online: 18-08-2022

Access this article online

Quick Response Code:



Website:
www.jmuonline.org

DOI:
[10.4103/jmu.jmu_51_22](https://doi.org/10.4103/jmu.jmu_51_22)

This is an open access journal, and articles are distributed under the terms of the Creative Commons Attribution-NonCommercial-ShareAlike 4.0 License, which allows others to remix, tweak, and build upon the work non-commercially, as long as appropriate credit is given and the new creations are licensed under the identical terms.

For reprints contact: WKHLRPMedknow_reprints@wolterskluwer.com

How to cite this article: Erdil D, Bagis N, Eren H, Camgoz M, Orhan K. The evaluation of the relationship between changes in masseter muscle thickness and tooth clenching habits of bruxism patients treated with botulinum toxin A. *J Med Ultrasound* 2023;31:22-8.

contributes approximately 43% of the total strength of the jaw closure muscles, the temporalis muscle approximately 36%, and the medial pterygoid muscle approximately 21%.^[11-13] Muscle hypertrophy as a result of long-term bruxism often occurs, and most commonly seen in masseter muscle among the masticatory muscles. Masseter hypertrophy described as an asymptomatic unilateral or bilateral volume raise of the masseter muscle. The hypertrophy is usually bilateral, but may be unilateral, depending on chewing habits.^[14] As a result of this situation, facial enlargement and an angular appearance occur.^[15]

Although there is not an agreed treatment method for bruxism, the application of botulinum toxin A (BT-A) has become an effective and reliable treatment method recently.^[16] When botulinum toxin is injected into the masseter and temporal muscles, it decreases the masticatory muscle contraction resulting from bruxism, and thus, minimizes the symptoms.^[17]

Ultrasonography is a reproducible and economical imaging modality that does not have the detrimental effects of ionizing radiation in the evaluation of muscle thickness compared to computed tomography (CT) or magnetic resonance imaging (MRI).^[18,19] Hence, the diagnosis of masseter hypertrophy can be confirmed with an easy, noninvasive and radiation-free method with the use of ultrasound (USG) in patients with facial asymmetry.^[14] Therefore, it can also be used to measure the masseter muscle thickness in bruxism patients. Thus, the effectiveness of treatment in individuals with masseter hypertrophy can easily be followed by ultrasonography.^[20,21]

This study aimed to evaluate the relationship between the changes in masseter muscle thickness using linear ultrasonography and clenching habits in bruxism patients treated with BT-A.

MATERIALS AND METHODS

Patient selection

Thirty-eight patients who were admitted to the Ankara University Faculty of Dentistry, Department of Periodontology with teeth grinding complaints and diagnosed as during sleep (sleep bruxism) were included in the study. The diagnosis of bruxism was established according to a self-report and clinical examination. The BT-A injection delivery into the masseter muscle was planned. The termination of muscle hypertrophy and/or the treatment of related temporomandibular dysfunction was the objective of the planned BT-A injection. The study was approved by the Ethical Committee of the Ankara University, Faculty of Dentistry (No: 36290600/53), and conducted according to the Helsinki Declaration. All individuals were informed about the study and written informed consent forms were collected.

Patients older than 18 years of age, patients with masseter muscle hypertrophy, patients with TMJ dysfunction resulting from muscle function, patients who were scheduled to receive

intramuscular BT-A injection application for the treatment of muscle hypertrophy, and patients who signed an informed consent form were included in the study.

Patients with masseter muscle or parotid gland pathologies, patients with previous parotid gland operation, patients with benign/malignant tumors of the mandible, patients with TMJ dysfunction other than muscle function, pregnant and breastfeeding women, and patients allergic to the components of BT-A were excluded.^[22]

Demographic data were collected from each patient. The Fonseca Anamnestic Index was applied to detect the bruxism level.^[23] Ultrasonography was conducted to evaluate the muscle dimensions.

Acquirement and evaluation of ultrasound records

The masseter muscle thickness of the individuals included in the study was evaluated at the baseline (P0), 3 (P1) and 6 (P2) months postoperatively by the aid of an ultrasound device present at the Department of Dentomaxillofacial Radiology (Aloka Prosound α6, Hitachi Aloka Medical, Tokyo, Japan). To standardize the muscle thickness measurements, a linear probe within 5–13 MHz was placed parallel to the lower edge of the mandibular corpus and transversely 1–2 cm above on the measurement side as described by Chang *et al.*^[24] Following this, when the patient was at rest (RST) and the maximum voluntary contraction (MVC), the thickness of the masseter muscle was measured at three points (the back junction edge of the masseter and parotid gland, and the thickest part in the middle and front edge line of ramus of the mandibula in the front) by moving the probe forward and backward. The measurements were in millimeters and the mean value was calculated [Figures 1-3]. The thickness of the masseter muscle at rest and MVC was therefore calculated separately. According to the baseline measurements, the diagnosis of

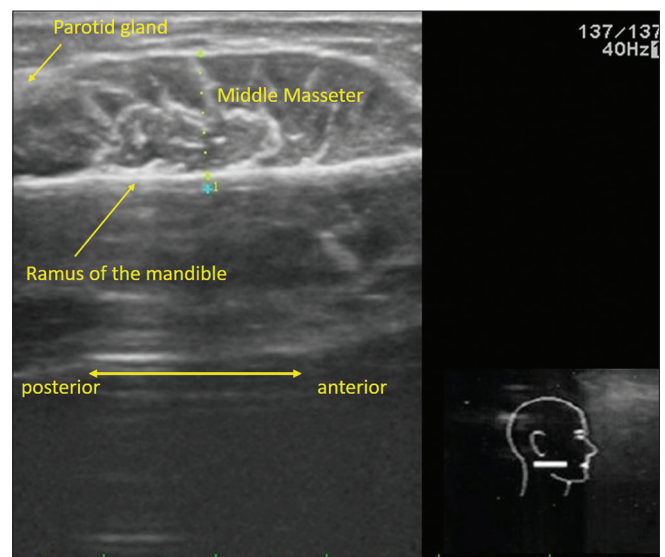


Figure 1: Right masseter muscle (MVC) mid-region USG evaluation. USG: Ultrasound, MVC: Maximum voluntary contraction

bilateral masseter hypertrophy was confirmed and treatment protocol was scheduled.

Treatment protocol

All the patients were informed about the possible side effects of the BT-A injection and written signed consent forms were collected from them. For a dose of 1.0 U/0.1 mL, 100-U frozen dried BT-A (Botox, Allergan, Inc., Irvine, CA) was diluted with 2 cc saline and 30-gauge injectors were used for all the injections. The patients were positioned horizontally according to the Frankfurt horizontal plane. After cleaning and drying the skin, to keep the injection in the safe zone, the back, front, top, and bottom borders of the masseter muscle were established. The three points of the injection were marked [Figure 4a]. The patients were instructed to clench their teeth so that the muscles and area of injection became more visible. The injector was placed vertically to the skin and the injections were applied [Figure 4b]. All the injections were performed by the same clinician (NB). A 25 U for each masseter and a total of 50 U for each patient was applied. The patients were recalled 2 weeks, 3 months, and 6 months after the injection.

Statistical analysis

In calculating the sample size of the study, the power test for each variable was determined as a minimum of 25 individuals by taking at least 80% and a Type 1 error of 5%. The Shapiro-Wilk test ($n < 50$) was used to determine whether the measurements in the study were normally distributed and since they were distributed normally, parametric tests were applied. The descriptive statistics for the continuous variables in our study

(mean, standard deviation, minimum and maximum; categorical variables) were expressed as numbers and percentages. The independent *t*-test or one-way analysis of variance test was used to compare the measurements according to the groups. The Chi-square test was used to determine the relationship between the categorical variables. The Pearson's correlation test was used to determine the relationship between the measurements. To compare the measurements, a paired *t*-test was conducted. The level of significance was taken to be (*P*) 5%, and the data were analyzed with the SPSS (IBM SPSS for Windows, ver. 25. SPSS Inc. Chicago, IL, USA) package.

RESULTS

Thirty-eight individuals diagnosed with bruxism and due to receive BT-A into the masseter muscle were included in the study. Thirteen incontinent patients were excluded from the study because they did not attend their follow-up appointments. The study was completed with 23 female and 2 male patients, with a total of 25. The age range was between 20 and 65 with a mean value of 32.25 ± 10.01 .

Patient classification according to the Fonseca Anamnestic Index

According to the Fonseca Anamnestic Index, which was conducted before the BT-A application; 6 patients had severe TMD, 11 had moderate TMD, 8 had mild TMD, and 2 did not have any TMD. The Fonseca Anamnestic Index application 6 months after the BT-A treatment revealed 3 patients with severe TMD, 11 with moderate TMD, 8 with mild TMD, and 3 patients had no TMD at all. According to the baseline index, 3 out of 6 people with severe TMD, changed from severe

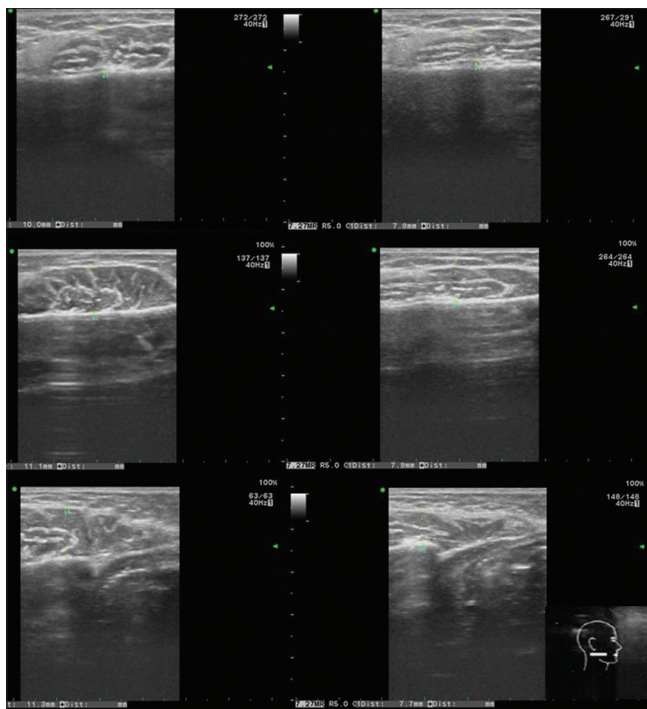


Figure 2: USG image of the right masseter muscle at RST and MVC. USG: Ultrasound, MVC: Maximum voluntary contraction, RST: Rest

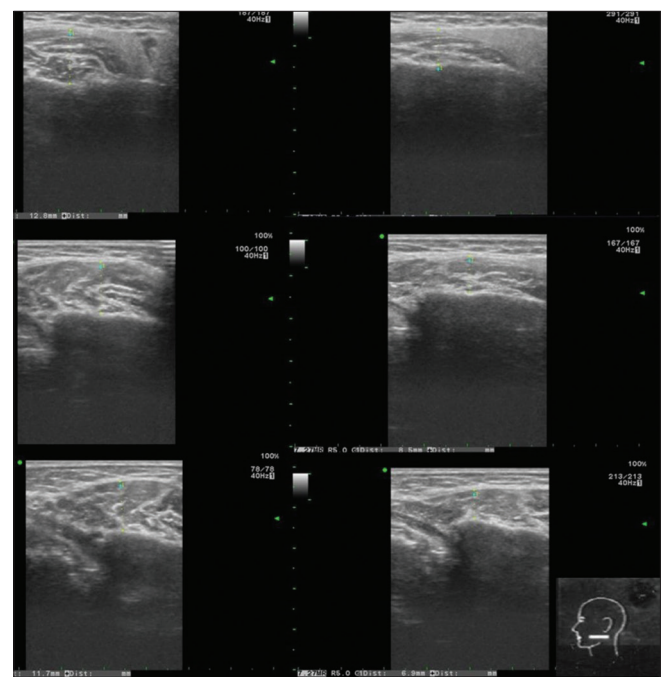


Figure 3: USG image of the left masseter muscle at RST and MVC. USG: Ultrasound, MVC: Maximum voluntary contraction, RST: Rest

to moderate TMD; it was observed that 3 of 11 people with moderate TMD decreased in severity and moved into the mild TMD and non-TMD group [Figure 5].

Relationship between Fonseca Anamnestic Index and masseter muscle thickness before and after treatment

Changes in Fonseca scores and masseter muscle thickness according to treatment are shown in Table 1. The results showed that masseter muscle thickness at the end of the treatment procedure (P2) has been decreased which is statistically significant ($P < 0.05$). Fonseca score which can be considered as an indicator of tooth clenching habit has been also decreased in parallel with muscle thickness, and this decrease was also statistically significant ($P < 0.05$).

Comparison of masseter muscle thickness before and after treatment

Comparisons of the ultrasonography measurements recorded at rest and the MVC of the right and left masseter muscles of the patients before the treatment, 3 months after the treatment and 6 months after the treatment are shown in Table 2 and Figure 6.

The ultrasonography measurements performed at P0-P1 and P0-P2 time points when the left masseter muscle was at rest revealed a decrease in muscle thickness, and this difference was statistically significant ($P < 0.05$). The difference between the P1 and P2 times was not statistically significant ($P > 0.05$) [Table 2].

According to the ultrasonography measurements done at the P0-P1 and P0-P2 time points with the left masseter muscle in the state of MVC, a decrease in muscle thickness was observed, and this difference was also statistically significant ($P < 0.05$). The difference between the P1 and P2 points was not significant ($P > 0.05$) [Table 2].

Table 1: Significance levels of pre- and post-treatment fonseca scores and changes in masseter muscle thickness according to paired *t*-test results

	Mean±SD	P*
Pretreatment fonseca score	50.00±19.58	0.015*
Posttreatment fonseca score	42.00±20.72	
Left masseter in rest		
P0	9.05±1.27	0.001*
P2	7.78±1.11	
Left masseter in MVC		
P0	12.68±1.92	0.001*
P2	10.90±1.72	
Right masseter in rest		
P0	8.68±1.28	0.024*
P2	7.91±1.42	
Right masseter in MVC		
P0	12.50±1.58	<0.001*
P2	11.08±1.50	

*P value indicates the statistically significant results of the compared data. MVC: Maximum voluntary contraction, SD: Standard deviation

The ultrasonography measurements performed at the P0-P1 and P0-P2 time points when the right masseter muscle was at rest revealed a decrease in muscle thickness and this difference was statistically significant ($P < 0.05$). The difference between the P1 and P2 points was not significant ($P > 0.05$) [Table 2].

The ultrasonography measurements obtained when the right masseter muscle was in the state of MVC at P0-P1 and P0-P2 time points showed a decrease in muscle thickness,

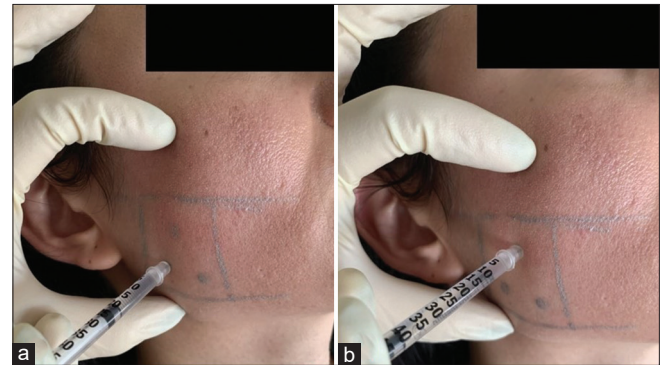

Figure 4: Three points determined for BT-A injection (a), and position of the injector over the injection points (b). BT-A: botulinum toxin A

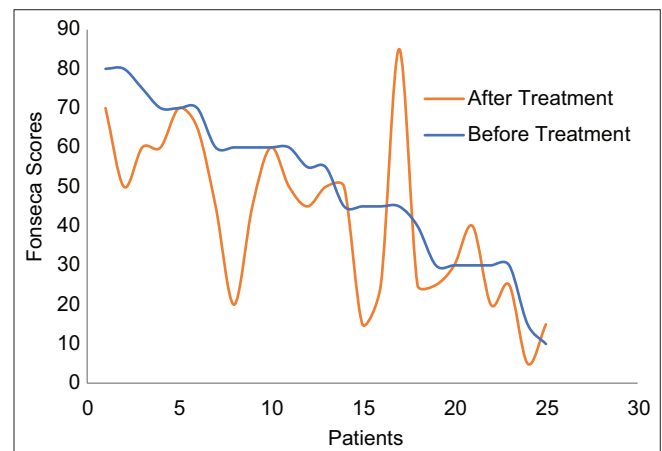


Figure 5: Classification of patients according to Fonseca Anamnestic Index

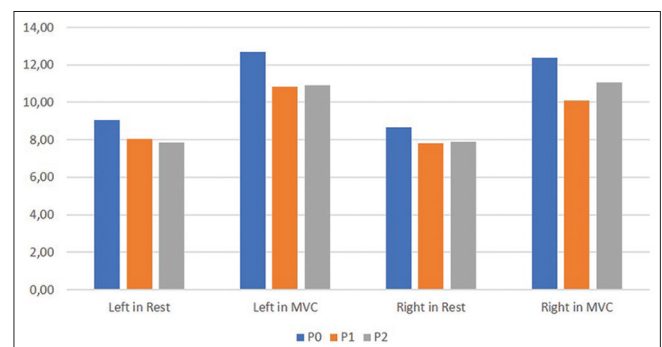


Figure 6: Pre- and post-treatment ultrasonographic measurements in 3 different time points which represents the change of masseter muscle in course of time

Table 2: Significance levels of pre- and post-treatment ultrasonographic values according to paired *t*-test results

	Mean±SD	P*
Left masseter in rest		
P0	9.05±1.29	0.008*
P1	8.05±1.27	
P0	9.05±1.27	0.001*
P2	7.78±1.11	
P1	8.05±1.27	0.557
P2	7.78±1.09	
Left masseter in MVC		
P0	12.68±2.16	0.002*
P1	10.85±1.77	
P0	12.68±1.92	0.001*
P2	10.90±1.72	
P1	10.85±1.77	0.943
P2	10.90±1.87	
Right masseter in rest		
P0	8.68±1.24	0.001*
P1	7.81±1.12	
P0	8.68±1.28	0.024*
P2	7.91±1.42	
P1	7.81±1.12	0.559
P2	7.91±1.54	
Right masseter in MVC		
P0	12.50±1.74	<0.001*
P1	10.09±1.72	
P0	12.50±1.58	<0.001*
P2	11.08±1.50	
P1	10.09±1.72	0.051
P2	11.08±1.57	

*P value indicates the statistically significant results of the compared data. MVC: Maximum voluntary contraction, SD: Standard deviation

and this difference was statistically significant ($P < 0.05$). The difference between the P1 and P2 points was not significant ($P > 0.05$) [Table 2].

DISCUSSION

The prevalence of bruxism in society has increased as the modern lifestyle brings stress along with it.^[25] It has been shown that bruxism may harm stomatognathic structures, cause hypertrophy of masticatory muscles, and myofascial pain.^[26] The treatment of bruxism aims to prevent these symptoms and improve quality of life.

Cavallo *et al.* used the Fonseca Anamnestic Index for the diagnosis of bruxism.^[27] Likewise, Nomura *et al.* and Nogueira Coutinho *et al.* used the Fonseca Anamnestic Index to diagnose both bruxism and TMJ dysfunctions.^[23,25-28] The index is a measure that can provide more information in a short period, be understood easily, and the patient is not affected by the applicator. Patients can easily be categorized according to the severity of bruxism and TMJ disorder. We used the easy and comprehensible Fonseca Anamnestic Index in compliance with these studies. The inclination in the scores detected 6 months

after the BT-A application was also parallel with the outcomes of these studies.

In our study, both clinical (presence of masseter hypertrophy) and ultrasonographic investigations were utilized. Therefore, it was possible to diagnose preexisting bruxism, verify the diagnosis radiologically, and follow up on the efficiency of the treatment at the same time. Although our primary goal was to define bruxism, being able to evaluate the effectiveness of our treatment numerically was also important. The literature search revealed a limited number of studies indicating the efficiency of the BT-A injection and masseter muscle contraction values with an ultrasound inspection in the long term.

Despite the many studies on prevalence, etiology, effects, and the treatment of bruxism, a guide or consensus on treatment has yet to be compiled. The management of bruxism mostly includes symptomatic; reversible, and conservative methods such as implementation of intraoral apparatus and/or physiotherapy. These methods intend to prevent bruxism-related harm rather than obtaining a therapeutic effect.^[29] One of the commonly used methods is the intraoral apparatus application. This application requires at least 6 months of utilization and strict compliance of the patient, whereas the botulinum toxin application does not require patient cooperation.^[30] Von Lindern *et al.* found significant healing with the BT-A application in the symptoms of 90 patients whose myofascial pain was unresponsive to conservative treatment.^[31] Yurttutan *et al.* compared the efficiency of occlusal splints with the BT-A application. They found that the utilization of occlusal splints does not provide additional benefits and there was more improvement in the BT-A application group.

There is not a certain and standard dosage in the BT-A injection for the bruxism treatment. Therefore, applied doses are different.^[32] This is also due to the existence of different types of commercial BT-A. The doses applied to masseter muscle ranges between 8U and 100U in various studies.^[33-36] In the present study, a 26 U BT-A (Botox, Allergan, Inc., Irvine, CA) application into each masseter muscle was found to be effective. The idea of a minimal effective dose application for the treatment of pathology and adjunctive applications for persistent and necessary situations that would lengthen the patient's relief is accepted. Additional applications were not required in our study. Our radiologic inspection 3 months after the application revealed a significant reduction in muscle thickness, which was stable 6 months after treatment. Depending on the outcomes of our study, it is possible to state that a single-dose BT-A application into the masseter muscle declines bruxism effectively and this state endures for 6 months.

While an increase in muscle volume and hypertrophy are observed because of muscle hyperactivity due to bruxism; muscle atrophy develops with paralysis and muscle volume gradually decreases after BT-A applications. Since the daily contraction amount will decrease with the abandonment of

the bruxism habit, the thinning of the face continues in the process.^[37] The reduction in masseter hypertrophy has been determined by different methods in the literature. Moore and Wood and Von Lindern *et al.* evaluated the declination in the volume of masseter muscle via clinical photographs.^[38,39] Eren *et al.* evaluated the change in the lower face due to the thinning of the masseter muscle in patients who underwent CT-A for the treatment of masseter hypertrophy using the “face scan” method, which is a face photograph provided by cone beam CT.^[40] Choe *et al.* used USG in evaluating masseter muscle, whereas Yu *et al.* investigated the change in masseter muscle volume with the help of CT.^[41,42] Some investigators used both USG and CT while evaluating the effect of BT-A on muscle volume.^[43,44] In our study, a simple, fast, and inexpensive USG method that does not contain radiation, was used to evaluate the effect of the BT-A treatment on masseter muscle hypertrophy and masseter muscle thickness.^[45] CT has limited use because it has a cumulative risky biological effect and MRI is expensive and difficult to access.^[43] It is known that the values obtained by USG in the evaluation of masseter muscle thickness shows a statistically significant correlation with MRI, and the reproducibility of muscle thickness measurements obtained by USG is high.^[18]

Different amounts of the thinning of the masseter muscle following a BT-A application have been reported.^[42,46] In a study by To *et al.*, ultrasound records and electromyography evaluation 3 months after the BT-A application into the masseter muscle revealed a 31% reduction in the masseter muscle volume. It was stated that 6 of the 9 masseter muscles included in the study preserved their atrophic state.^[47] In another study, the masseter muscle volume was evaluated by a USG and a decrease of up to 60% was observed in the volume, and it was determined that the maximum decrease was in the 3rd month.^[48] Our evaluation of ultrasound records indicated a significant thinning of the masseter muscle at rest and MVC 3 and 6 months after BT-A application compared to baseline. This complied with the literature. In addition, similar to the literature, the decrease in the 3rd month was higher in our study.

The present study has some limitations including lack of a control group with or without placebo injection and interobserver and intraobserver reliability even though the observer is experienced in ultrasound scanning of masticatory muscles. However, the aim of the study was to primarily focus on follow-up process of masseter hypertrophy treatment and its effect on changes in clenching habits. Although there is no control group, the clinical significance level of the obtained results is considered to be sufficient.

CONCLUSION

The BT-A application is an effective and safe method with no side effects in the treatment of masseter muscle hypertrophy due to bruxism, and for eliminating the habit. The treated patients gave positive feedback and the bruxism scores

declined. The BT-A application is also effective for masseter muscle hypertrophy. The maximum reduction was observed in the 3rd month and muscle thickness remained stable from the 3rd to 6th month.

Financial support and sponsorship

Nil.

Conflicts of interest

There are no conflicts of interest.

REFERENCES

1. Lobbezoo F, Ahlberg J, Raphael KG, Wetselaar P, Glaros AG, Kato T, *et al.* International consensus on the assessment of bruxism: Report of a work in progress. *J Oral Rehabil* 2018;45:837-44.
2. Kato T, Thie NM, Huynh N, Miyawaki S, Lavigne GJ. Topical review: Sleep bruxism and the role of peripheral sensory influences. *J Orofac Pain* 2003;17:191-213.
3. Manfredini D, De Laat A, Winocur E, Ahlberg J. Why not stop looking at bruxism as a black/white condition? Aetiology could be unrelated to clinical consequences. *J Oral Rehabil* 2016;43:799-801.
4. Johansson A, Omar R, Carlsson GE. Bruxism and prosthetic treatment: A critical review. *J Prosthodont Res* 2011;55:127-36.
5. Glaros AG, Williams K. Tooth contact versus clenching: Oral parafunctions and facial pain. *J Orofac Pain* 2012;26:176-80.
6. Okeson JP. Etiology of functional disturbances in the masticatory system. *Manage Temporomandibular Disord Occlusion* 2013;7:130-63.
7. Carlsson GE, Egermark I, Magnusson T. Predictors of bruxism, other oral parafunctions, and tooth wear over a 20-year follow-up period. *J Orofac Pain* 2003;17:50-7.
8. Manfredini D, Lobbezoo F. Role of psychosocial factors in the etiology of bruxism. *J Orofac Pain* 2009;23:153-66.
9. Przysańska A, Jasielska A, Ziarko M, Pobudek-Radzikowska M, Maciejewska-Szaniec Z, Prylińska-Czyżewska A, *et al.* Psychosocial predictors of bruxism. *Biomed Res Int* 2019;2019:2069716.
10. Gungormus Z, Erciyas K. Evaluation of the relationship between anxiety and depression and bruxism. *J Int Med Res* 2009;37:547-50.
11. Weijs WA, Hillen B. Cross-sectional areas and estimated intrinsic strength of the human jaw muscles. *Acta Morphol Neerl Scand* 1985;23:267-74.
12. Peck CC. Biomechanics of occlusion – Implications for oral rehabilitation. *J Oral Rehabil* 2016;43:205-14.
13. Ingawalé SM, Goswami T. Biomechanic of the temporomandibular joint. In: Goswami T, editor. *Human Musculoskeletal Biomechanics*. 1st ed. London: InTech; 2012. p. 159-82.
14. Eren H, Gorgun S. Use of ultrasound in the assessment of masticatory muscles. *Turk Klin J Oral Maxillofac Radiol Spec Top* 2016;2:1-6.
15. Aguilera SB, Brown L, Perico VA. Aesthetic treatment of bruxism. *J Clin Aesthet Dermatol* 2017;10:49-55.
16. Fernández-Núñez T, Amghar-Maach S, Gay-Escoda C. Efficacy of botulinum toxin in the treatment of bruxism: Systematic review. *Med Oral Patol Oral Cir Bucal* 2019;24:e416-24.
17. Kumar A, Spivakovsky S. Bruxism- is botulinum toxin an effective treatment? *Evid Based Dent* 2018;19:59.
18. Raadsheer MC, Van Eijden TM, Van Spronsen PH, Van Ginkel FC, Kiliaridis S, Prah Andersen B. A comparison of human masseter muscle thickness measured by ultrasonography and magnetic resonance imaging. *Arch Oral Biol* 1994;39:1079-84.
19. Kiliaridis S, Kälébo P. Masseter muscle thickness measured by ultrasonography and its relation to facial morphology. *J Dent Res* 1991;70:1262-5.
20. Bakke M, Tuxen A, Vilmann P, Jensen BR, Vilmann A, Toft M. Ultrasound image of human masseter muscle related to bite force, electromyography, facial morphology, and occlusal factors. *Scand J Dent Res* 1992;100:164-71.
21. Han DS, Wu WT, Hsu PC, Chang HC, Huang KC, Chang KV. Sarcopenia is associated with increased risks of rotator cuff tendon diseases among

- community-dwelling elders: A cross-sectional quantitative ultrasound study. *Front Med (Lausanne)* 2021;8:630009.
22. Erdil D, Bagis N, Eren H, Camgoz M, Orhan K. Evaluation of changes in depression levels of bruxism patients treated with botulinum Toxin-A. *J Adv Oral Res* 2021;12:200-5.
23. Nomura K, Vitti M, Oliveira AS, Chaves TC, Semprini M, Siéssere S, *et al.* Use of the Fonseca's questionnaire to assess the prevalence and severity of temporomandibular disorders in Brazilian dental undergraduates. *Braz Dent J* 2007;18:163-7.
24. Chang PH, Chen YJ, Chang KV, Wu WT, Özçakar L. Ultrasound measurements of superficial and deep masticatory muscles in various postures: Reliability and influencers. *Sci Rep* 2020;10:14357.
25. Wieckiewicz M, Paradowska-Stolarz A, Wieckiewicz W. Psychosocial aspects of bruxism: The most paramount factor influencing teeth grinding. *Biomed Res Int* 2014;2014:469187.
26. Dharmadhikari S, Romito LM, Dziedzic M, Dydak U, Xu J, Bodkin CL, *et al.* GABA and glutamate levels in occlusal splint-wearing males with possible bruxism. *Arch Oral Biol* 2015;60:1021-9.
27. Cavallo P, Carpinelli L, Savarese G. Perceived stress and bruxism in university students. *BMC Res Notes* 2016;9:514.
28. Nogueira Coutinho E, Pereira Rodrigues Dos Santos K, Henrique Barros Ferreira E, Grailea Silva Pinto R, de Oliveira Sanchez M. Association between self-reported sleep bruxism and temporomandibular disorder in undergraduate students from Brazil. *Cranio* 2020;38:91-8.
29. Guarda-Nardini L, Manfredini D, Salomone M, Salmaso L, Tonello S, Ferronato G. Efficacy of botulinum toxin in treating myofascial pain in bruxers: A controlled placebo pilot study. *Cranio* 2008;26:126-35.
30. Yurtutan ME, Tütüncüler Sancak K, Tüzüner AM. Which treatment is effective for bruxism: occlusal splints or botulinum toxin? *J Oral Maxillofac Surg* 2019;77:2431-8.
31. Von Lindern JJ, Niederhagen B, Bergé S, Appel T. Type A botulinum toxin in the treatment of chronic facial pain associated with masticatory hyperactivity. *J Oral Maxillofac Surg* 2003;61:774-8.
32. De la Torre Canales G, Câmara-Souza MB, do Amaral CF, Garcia RC, Manfredini D. Is there enough evidence to use botulinum toxin injections for bruxism management? A systematic literature review. *Clin Oral Investig* 2017;21:727-34.
33. Dressler D, Saberi FA, Barbosa ER. Botulinum toxin: Mechanisms of action. *Arq Neuropsiquiatr* 2005;63:180-5.
34. Bolayir G, Bolayir E, Coskun A, Ozdemir AK, Topaktas S. Botulinum toxin type-A practice in bruxism cases. *Neurol Psychiatry Brain Res* 2005;12:43-6.
35. American Academy of Sleep Medicine. Developmental or neuropsychiatric sleep disorders: Sleep bruxism (306.8). In: *International Classification of Sleep Disorders, Revised: Diagnostic and Coding Manual*. 3rd ed. Chicago, Illinois: American Academy of Sleep Medicine; 2001. p. 184-5.
36. Long H, Liao Z, Wang Y, Liao L, Lai W. Efficacy of botulinum toxins on bruxism: An evidence-based review. *Int Dent J* 2012;62:1-5.
37. Kim NH, Chung JH, Park RH, Park JB. The use of botulinum toxin type A in aesthetic mandibular contouring. *Plast Reconstr Surg* 2005;115:919-30.
38. Moore AP, Wood GD. The medical management of masseteric hypertrophy with botulinum toxin type A. *Br J Oral Maxillofac Surg* 1994;32:26-8.
39. von Lindern JJ, Niederhagen B, Appel T, Bergé S, Reich RH. Type A botulinum toxin for the treatment of hypertrophy of the masseter and temporal muscles: An alternative treatment. *Plast Reconstr Surg* 2001;107:327-32.
40. Eren H, Bagis N, Orhan K. Use of ultrasonography and face scan in the follow-up of masseter hypertrophy management: Two cases. *Turk Clin J Dent Sci* 2020;26:521-7.
41. Choe SW, Cho WI, Lee CK, Seo SJ. Effects of botulinum toxin type A on contouring of the lower face. *Dermatol Surg* 2005;31:502-7.
42. Yu CC, Chen PK, Chen YR. Botulinum toxin A for lower facial contouring: A prospective study. *Aesthetic Plast Surg* 2007;31:445-51.
43. Park MY, Ahn KY, Jung DS. Botulinum toxin type A treatment for contouring of the lower face. *Dermatol Surg* 2003;29:477-83.
44. Kim JH, Shin JH, Kim ST, Kim CY. Effects of two different units of botulinum toxin type A evaluated by computed tomography and electromyographic measurements of human masseter muscle. *Plast Reconstr Surg* 2007;119:711-7.
45. Park KM, Choi E, Kwak EJ, Kim S, Park W, Jeong JS, *et al.* The relationship between masseter muscle thickness measured by ultrasonography and facial profile in young Korean adults. *Imaging Sci Dent* 2018;48:213-21.
46. Kim HJ, Yum KW, Lee SS, Heo MS, Seo K. Effects of botulinum toxin type A on bilateral masseteric hypertrophy evaluated with computed tomographic measurement. *Dermatol Surg* 2003;29:484-9.
47. To EW, Ahuja AT, Ho WS, King WW, Wong WK, Pang PC, *et al.* A prospective study of the effect of botulinum toxin A on masseteric muscle hypertrophy with ultrasonographic and electromyographic measurement. *Br J Plast Surg* 2001;54:197-200.
48. Quezada-Gaon N, Wortsman X, Peñaloza O, Carrasco JE. Comparison of clinical marking and ultrasound-guided injection of Botulinum type A toxin into the masseter muscles for treating bruxism and its cosmetic effects. *J Cosmet Dermatol* 2016;15:238-44.